

CBI

Heymann Nephritis Immune Mediated FX-1-induced Glomerular Nephritis

Comparative Biosciences, Inc.
786 Lucerne Drive
Sunnyvale, CA 94085
Telephone: 408.738.9261
www.compbio.com



COMPARATIVE BIOSCIENCES, INC.
A TRANSLATIONAL APPROACH TO PRECLINICAL RESEARCH

HEYMANN NEPHRITIS

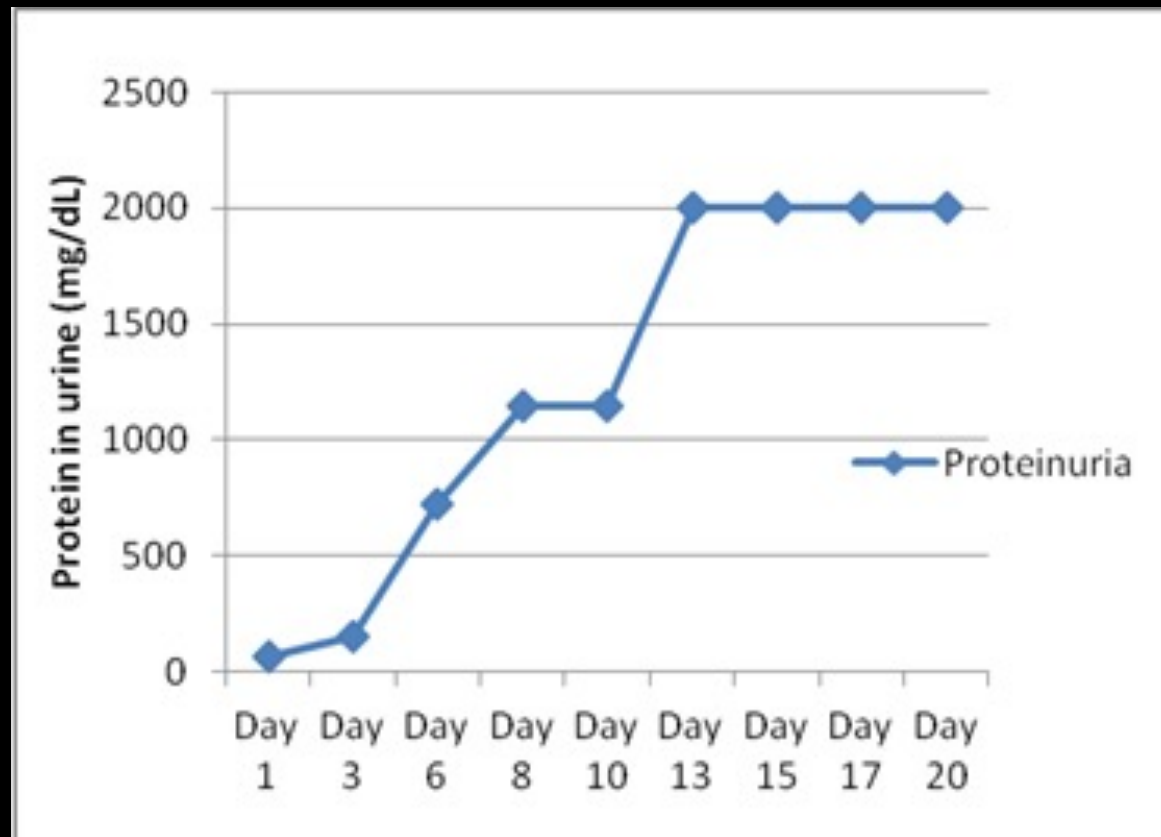
Immune mediated FX-1-induced glomerular nephritis

- Passive Heymann nephritis in rats resembles membranous nephropathy in man. It is induced by injection of sheep antibody to rat proximal tubular epithelial cell brush border antigen (anti-Fx1A).
- This is a robust and validated model at CBI.
- Induce with administration of optimal concentrations anti-Fx1A IgG in rats administered as a single systemic dose in CFA
- Urine changes-marked increases in urinary protein, creatinine and protein/creatinine ratios due to glomerular damage beginning within one week and increasing over 2-3 weeks
- Glomerular histologic changes of glomerular hypercellularity, inflammation and deposition visible by 3 weeks histologically
- Positive controls-not well understood, steroids not effective, mycophenolate mofetil show some activity



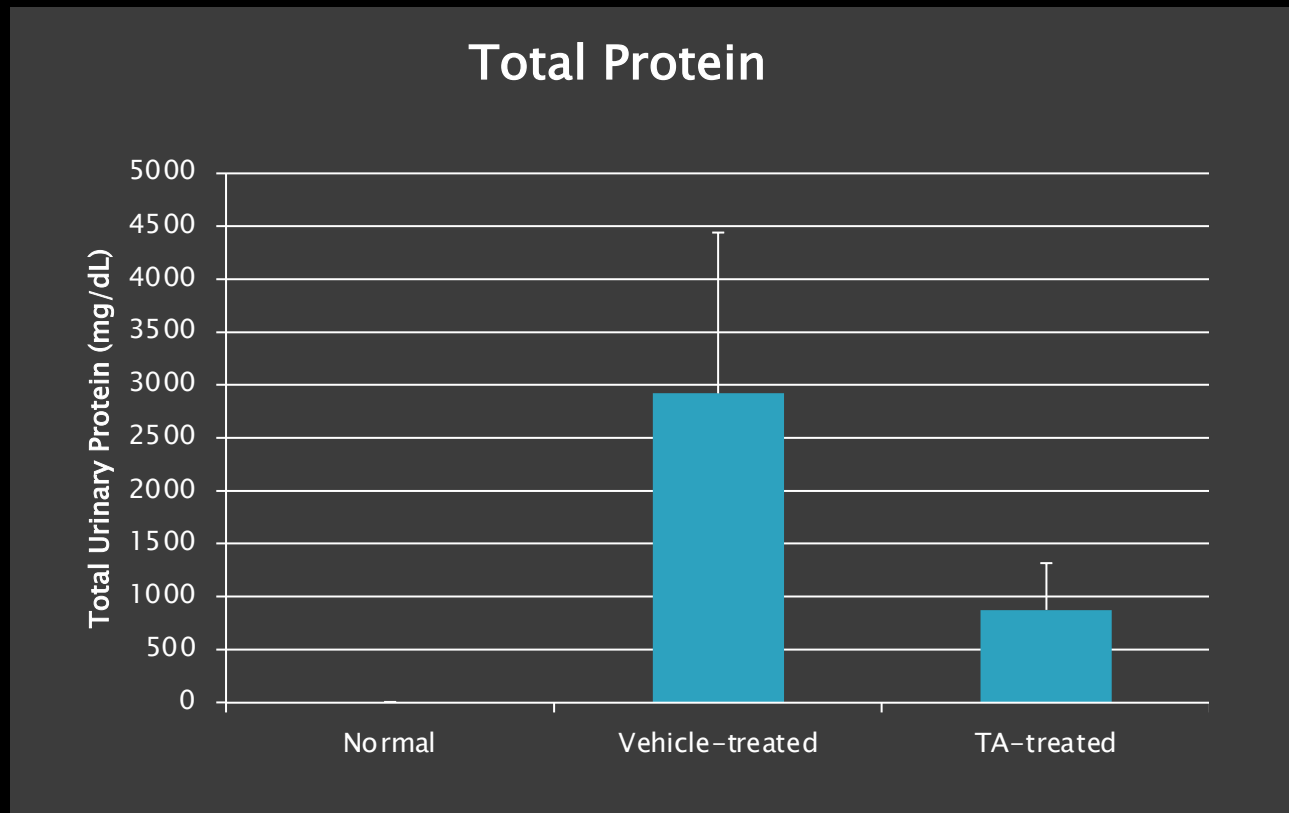
HEYMANN NEPHRITIS

Immune mediated FX-1-induced glomerular nephritis
Urine protein excretion increases beginning about Day 8



HEYMANN NEPHRITIS

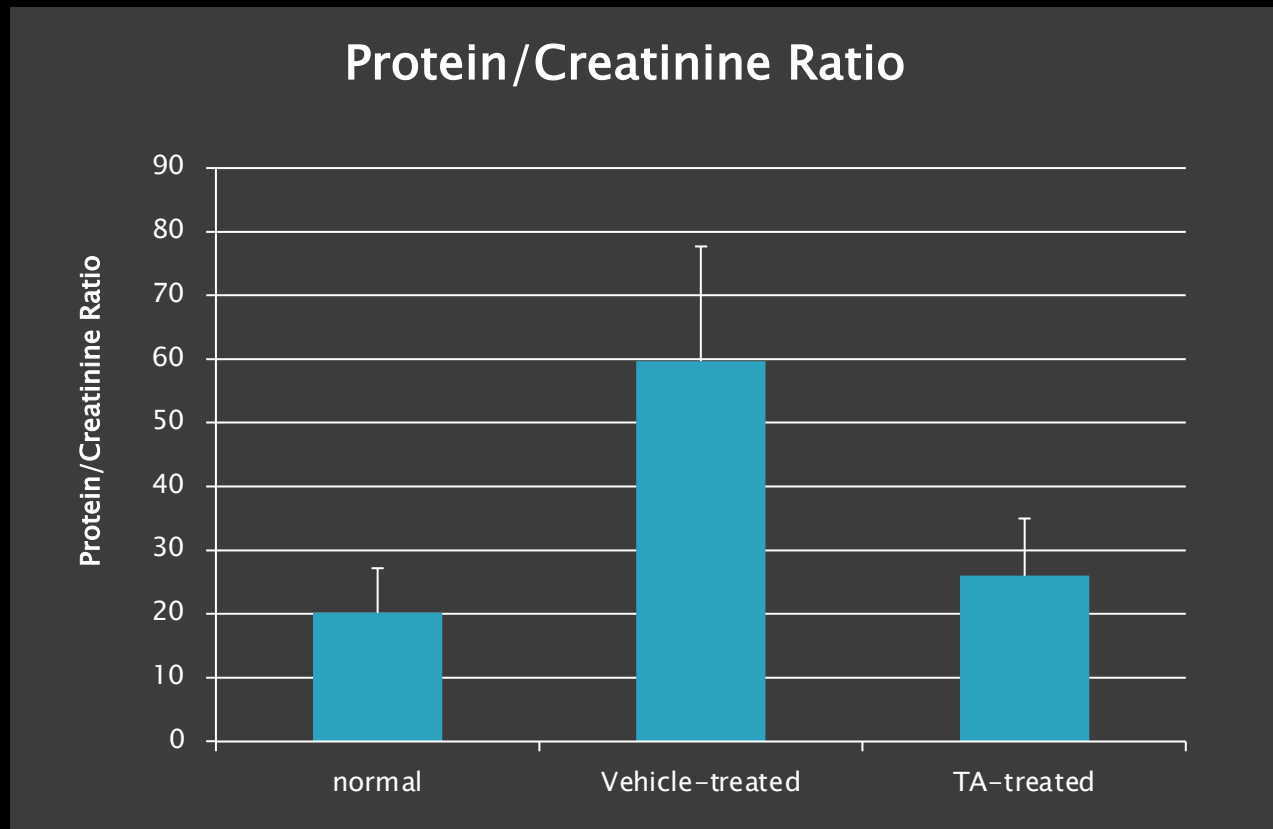
Immune mediated FX-1-induced glomerular nephritis
Total urine protein (Day 21) is markedly increased



HEYMANN NEPHRITIS

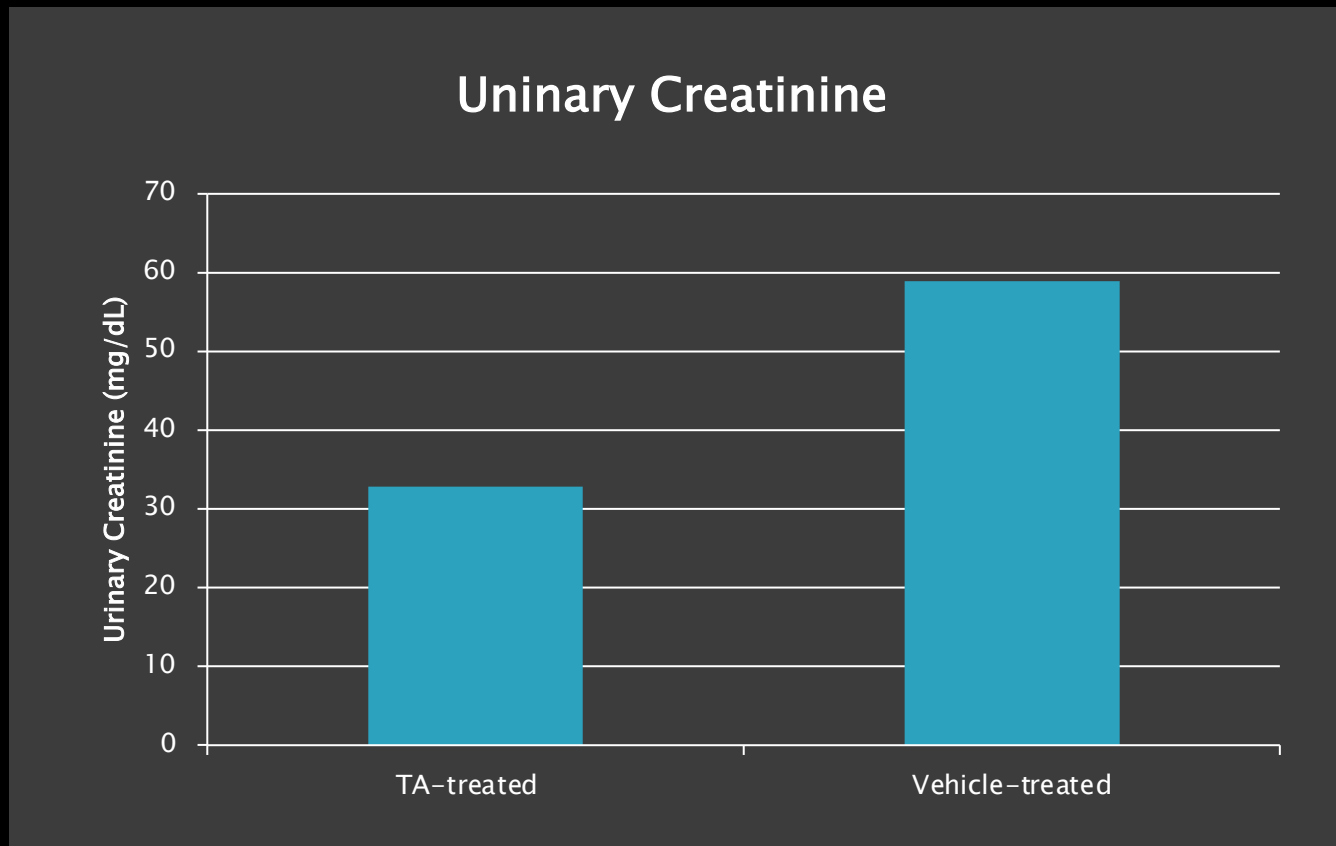
Immune mediated FX-1-induced glomerular nephritis

Urine protein/creatinine ratio (Day 21) is markedly increased



HEYMANN NEPHRITIS

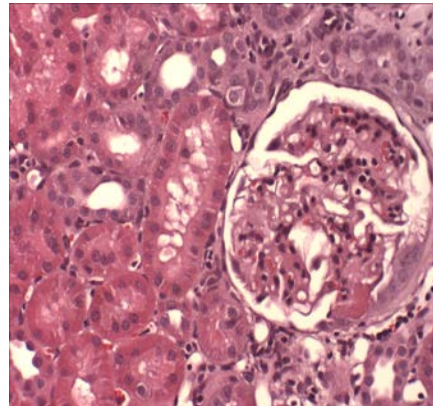
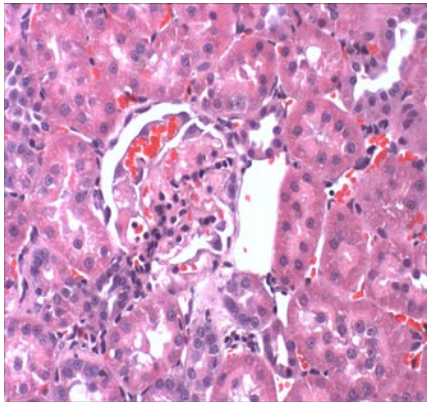
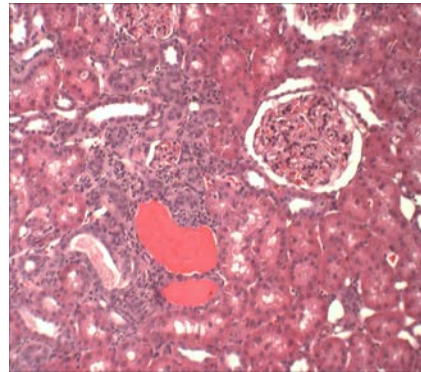
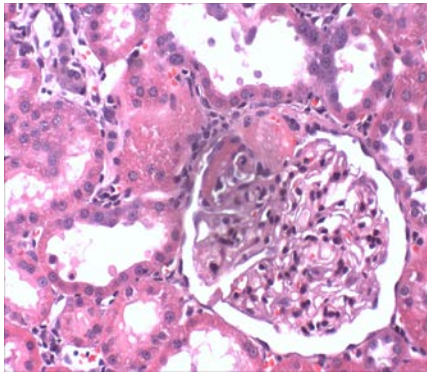
Immune mediated FX-1-induced glomerular nephritis
Urinary creatinine (Day 21) is markedly increased



HEYMANN NEPHRITIS

Immune mediated FX-1-induced glomerular nephritis

HISTOPATHOLOGY



Characteristic Glomerular Lesions

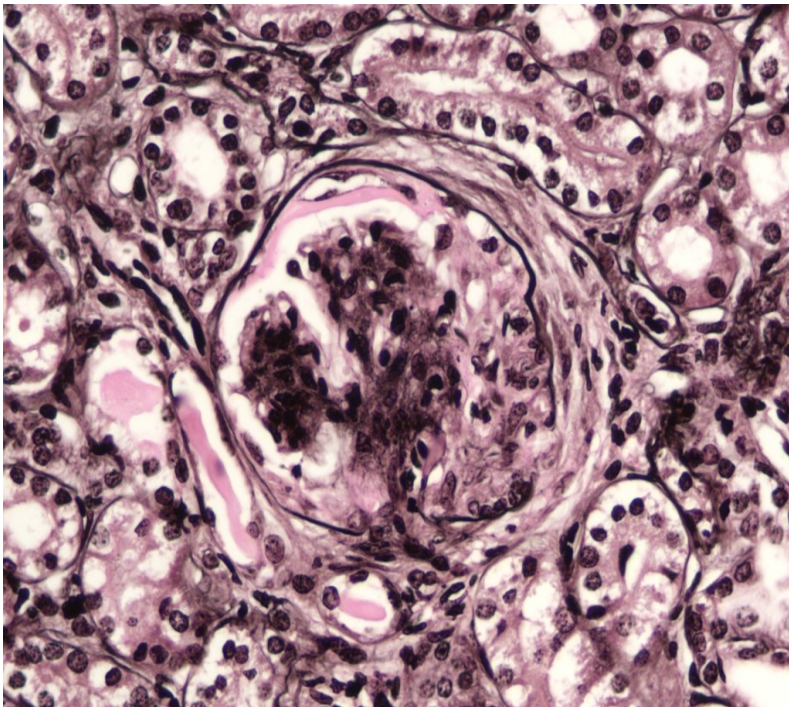
- Glomerular hypercellularity with eosinophilic deposition, inflammation, and wire loop lesions
- Hyperplasia of the Bowman's capsule
- Proteinic material in tubules and tubular dilation
- Interstitial lymphocytic inflammation



HEYMANN NEPHRITIS

Immune mediated FX-1-induced glomerular nephritis

HISTOPATHOLOGY



- Light microscopic examination
- Standard stains-HE, Trichrome, Sirius Red, Periodic acid Schiff, Jones methenamine silver stains
- Immunohistochemistry-collagen, SMA, basement membrane, inflammation
- Semi-quantitative assessment
- Option for histomorphometry

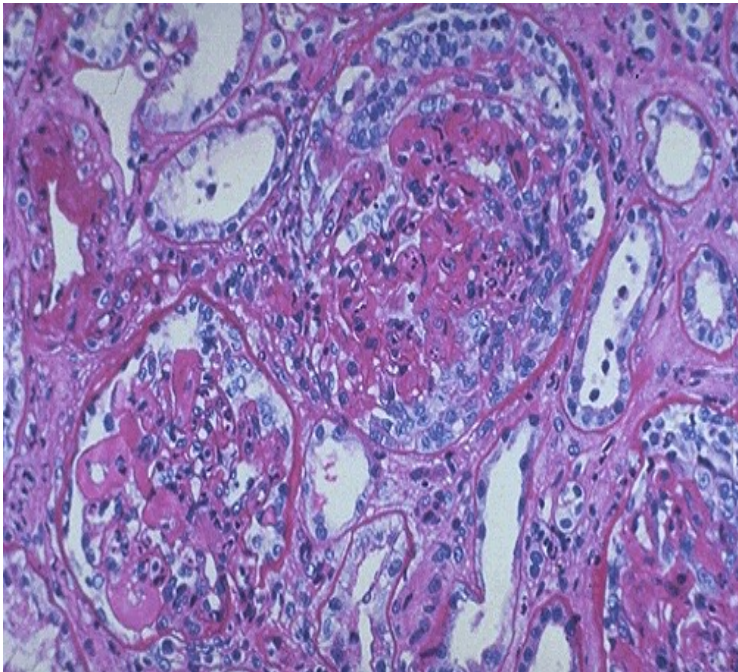




HEYMANN NEPHRITIS

Immune mediated FX-1-induced glomerular nephritis

HISTOLOGIC SCORING SYSTEM



- Assessment by ACVP Veterinary Pathologist
- Entire kidney and subparts of the nephron assessed
- Glomerulus, mesangium, basement membrane, Bowman's capsule, cellular infiltrates, tubules, interstitium
- Incidence and severity of the lesions were scored using the accepted industry scoring system of 0-4, corresponding to normal, minimal, mild, moderate, and severe, respectively.
- Lesions scored for duration (acute, subacute, and chronic) and distribution (focal, multifocal, diffuse) based on the composition and numbers of cell types present

SUMMARY

- Heymann Nephritis Immune mediated FX-1-induced glomerular nephritis is an established, robust, reproducible model at CBI
- Rats are administered the FX-1 antibody
- Urine changes-marked increases in urinary protein, creatinine and protein/creatinine ratios due to glomerular damage beginning within one week and increasing over 2-3 weeks
- Glomerular histologic changes of glomerular hypercellularity, inflammation and deposition visible by 3 weeks histologically

